Journal of Health Sciences and Medical Development
Vol. 5, No. 03, pp. 175-189
journal.iistr.org/index.php/HESMED
DOI: 10.56741/hesmed.v5i03.2779

Caudate Nucleus Hemorrhage Presenting as Vertigo in a Young Adult

A Case Report on Diagnostic Challenges and Medication Safety in Acute Care

[1]Susilo, [2]Ferina Angelia*, [1]Steven Sakasasmita
Corresponding Author: *ferina.angelia@ukrida.ac.id
[1] Universitas Kristen Krida Wacana, Jakarta, Indonesia

ARTICLE INFO

Article history
Received 8 October 2026
Revised 3 November 2026
Accepted 8 November 2026

ABSTRACT

Caudate nucleus hemorrhage in young adults without a history of hypertension is uncommon and may present with atypical clinical features. This case report describes the diagnostic challenges of caudate nucleus hemorrhage initially mimicking peripheral vertigo and highlights its implications for acute-phase medication safety. A 28-year-old woman without a history of hypertension presented to the emergency department with severe rotatory vertigo, nausea, and recurrent vomiting, without obvious focal neurological deficits. Her initial blood pressure was 114/67 mmHg, and the preliminary evaluation favored a peripheral vestibular etiology. Because the symptoms persisted and vomiting was severe, non-contrast head computed tomography (CT) was performed, revealing a right caudate nucleus hemorrhage extending into the right lateral and third ventricles, accompanied by ventriculomegaly. Following the diagnosis, the pharmacotherapy regimen was reassessed and adjusted, and mannitol was administered as hyperosmolar therapy. By day 3, the patient's headache and vertigo had improved, while consciousness remained stable. Follow-up was limited to the third day of hospitalization, and long-term outcomes were unavailable. This case highlights that severe or persistent vestibular symptoms do not exclude a central intracranial cause. In young adults with ICH without a history of hypertension, evaluation for secondary etiologies should be considered. Furthermore, medication reconciliation and individualized reassessment of drug indications and potential risks are essential components of medication safety during acute neurological emergencies.

Keywords
Caudate Nucleus
Hemorrhage
Intraventricular
Medication Reconciliation
Nonhypertensive
Vertigo

This is an open-access article under the CC–BY-SA license.

Introduction

Intracerebral hemorrhage (ICH) is a neurological emergency associated with a high risk of early clinical deterioration, thus necessitating rapid confirmation through neuroimaging [1]. The clinical characteristics and etiologies of ICH in young adults differ from those in older populations. An analysis by Wang et al. (2024) indicated that ICH imposes a significant disease burden in younger demographics, with elevated systolic blood pressure acting as a major contributor [2]. Although hypertension is widely recognized as a primary trigger for stroke, the etiologies of ICH in young adults are considerably more diverse—encompassing vascular, structural, and hematological factors, as well as substance use—making the investigation of secondary etiologies highly crucial [3], [4].

In young adults presenting with deep ICH without a history of hypertension, a macrovascular evaluation (such as for arteriovenous malformations [AVMs], aneurysms, cavernous malformations, or cerebral venous thrombosis) must be considered. Greenberg et al. (2022) recommended computed tomography angiography (CTA) for high-risk groups, and digital subtraction angiography (DSA) as the primary diagnostic reference for patients aged <45 years if the CTA is non-diagnostic. Magnetic resonance angiography (MRA) may also complement the evaluation based on clinical findings and initial imaging [1].

Caudate nucleus hemorrhage is a rare manifestation with an atypical presentation. Its close proximity to the ventricular system poses a risk for intraventricular extension [5]. The primary symptoms do not always involve focal motor deficits; rather, headache and vomiting have been reported as common clinical manifestations [6]. In the present case, however, the predominant initial complaint was severe rotatory vertigo accompanied by recurrent vomiting, without obvious focal neurological deficits. This vestibular-dominant presentation initially suggested a peripheral vestibular disorder, illustrating the potential for caudate nucleus hemorrhage to mimic a peripheral vestibular condition and delay recognition of an underlying central intracranial lesion.

Therefore, the evaluation of acute dizziness and vertigo, such as acute vestibular syndrome (AVS), must adopt a syndrome-based approach. The Head-Impulse, Nystagmus, Test of Skew (HINTS) clinical examination performed by a trained clinician can differentiate between central and peripheral etiologies. Although a brain CT scan is not a routine screening

modality for all AVS cases, it is indicated if symptoms are persistent, exceptionally severe, or if a structural process is suspected [7]. A diagnosis of "vertigo" should not be made as a final conclusion until central etiologies have been definitively ruled out.

The clinical significance and originality of this case report lie in the combination of three clinically relevant aspects: the unusual vestibular presentation of caudate nucleus hemorrhage, characterized by severe rotatory vertigo and recurrent vomiting that initially mimicked peripheral vertigo; the occurrence of ICH in a young adult without a history of hypertension; and medication safety considerations during the acute phase of care. In particular, this report highlights the importance of medication reconciliation and the reassessment of medication indications, potential risks, and appropriateness following the diagnosis of ICH. By bringing these aspects together, this report aims to describe the atypical clinical presentation, emphasize the importance of considering secondary intracranial etiologies in young adults without a history of hypertension, and highlight the role of medication safety in the pharmacological management of acute ICH.

Case Presentation

A 28-year-old female presented to the emergency department (ED) with complaints of severe rotatory dizziness since the previous night, accompanied by nausea and vomiting more than three times, resulting in an inability to tolerate oral intake. The patient denied dyspnea, cough, and rhinorrhea. Past medical history, including hypertension, allergies, and prior surgical procedures, was also denied. Prior to admission, the patient had received treatment at another healthcare facility comprising omeprazole 40 mg, ondansetron 8 mg, betahistine 6 mg, diphenhydramine, and paracetamol. These data represent the actual medication history prior to evaluation at the reporting hospital.

Upon arrival at the ED, the patient appeared moderately ill but remained fully conscious with a Glasgow Coma Scale (GCS) score of E4V5M6. Hemodynamic status was stable, with a blood pressure of 114/67 mmHg, heart rate of 76 beats/minute, respiratory rate of 19 breaths/minute, body temperature of 36.8°C, and oxygen saturation of 98% on room air. Initial neurological examination revealed no hemiparesis; extremity motor strength was symmetrical, and no pathological reflexes were elicited. No overt meningeal signs were observed. Pulmonary examination revealed vesicular breath sounds without crackles or wheezing.

Initial laboratory investigations showed a leukocyte count of 12,620/µL, a neutrophil-to-lymphocyte ratio of 16.48, hemoglobin of 11.5 g/dL, hematocrit of 34%, and creatinine of 0.56 mg/dL, with serum electrolytes within normal limits. Antigen tests for severe acute respiratory syndrome coronavirus 2 (SARS-CoV-2), dengue nonstructural protein 1 (NS1), and influenza A and B were negative. Chest radiography showed no cardiomegaly and was suggestive of bronchopneumonia. Based on the initial evaluation, the patient was diagnosed

with peripheral vertigo and bronchopneumonia with a Pneumonia Severity Index (PSI) score of 18. Chest radiography performed during the initial evaluation showed a cardiac silhouette within normal limits, with no evidence of cardiomegaly. The accompanying radiology report described findings suggestive of bronchopneumonia (Fig. 1).

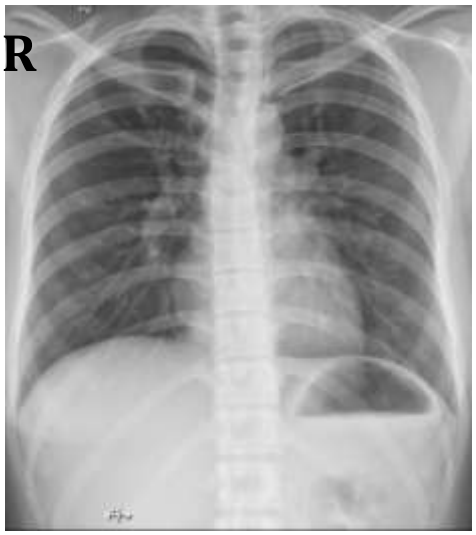

Source: Patient's medical record

Fig. 1. Chest radiograph at initial evaluation. The cardiac silhouette is within normal limits, with no evidence of cardiomegaly. The accompanying radiology report suggested bronchopneumonia

Due to persistent rotatory dizziness unresponsive to initial therapy and accompanied by severe vomiting, a non-contrast head computed tomography (CT) scan was performed. The scan revealed a hyperdense lesion centered in the right caudate nucleus, with an attenuation of approximately 60–75 Hounsfield units (HU) and extension into the anterior horn of the right lateral ventricle and the third ventricle. Dilatation of the ventricular system (ventriculomegaly) was also observed. These findings were consistent with a right caudate nucleus intracerebral hemorrhage (ICH) with intraventricular extension and ventriculomegaly (Fig. 2).

Before the definitive diagnosis was established, the patient received supportive, empiric, and symptomatic treatment. The medications and interventions administered included intravenous fluid therapy; intravenous ceftriaxone (2 g once daily); oral azithromycin (500 mg once daily); intravenous ondansetron; sucralfate; dimenhydrinate twice daily; betahistine (24 mg twice daily); flunarizine (5 mg twice daily); intravenous ketorolac; and inhalation/nebulization therapy with salbutamol, ipratropium bromide, budesonide, and bromhexine hydrochloride. Notably, the bromhexine hydrochloride preparation was an oral solution that was administered via nebulization in this case; this route is reported as documented in the actual clinical practice. The patient also received codeine (20 mg three times daily) as empiric antitussive therapy based on the initial working diagnosis of

bronchopneumonia, as well as a sustained-release combination preparation containing loratadine and pseudoephedrine hydrochloride. All medication names in this report are presented using their generic or active substance names.

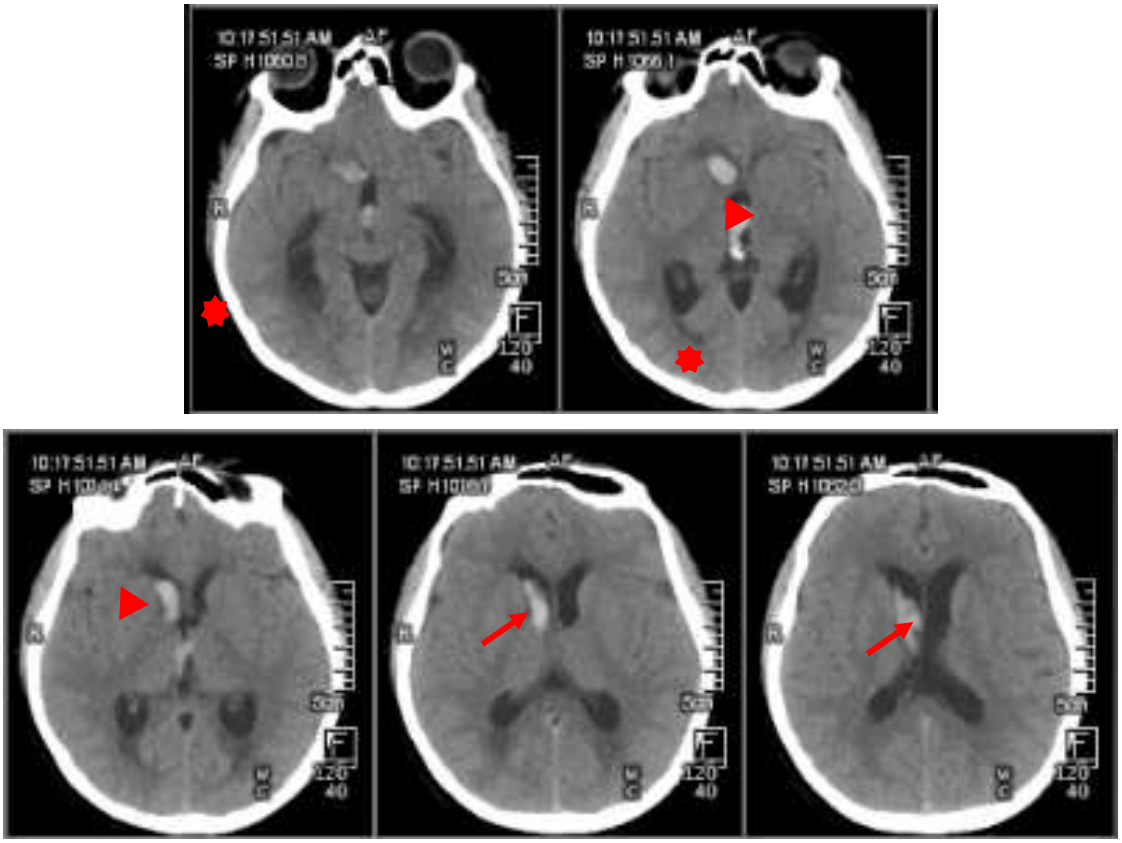

Source: Patient's medical record

Note: Axial CT images show a hyperdense hemorrhagic lesion centered in the right caudate nucleus (arrow →), with extension into the right lateral ventricle and third ventricle (arrowheads ▶). Dilatation of the ventricular system, consistent with ventriculomegaly, is also evident (asterisks*).

Fig. 2. Non-contrast head CT scan demonstrating right caudate nucleus hemorrhage with intraventricular extension and ventriculomegaly

Following the identification of the intracranial hemorrhage, the pharmacotherapy regimen was re-evaluated, and therapy was adjusted according to the patient's neurological condition. Medications that were no longer required or possessed risk profiles relevant to the clinical condition were reassessed through a medication reconciliation process. The patient was subsequently administered 20% mannitol 200 mL intravenously over 30 minutes, followed by 100 mL six times a day, which was later tapered to three times a day according to the treatment records. By the third day, the intensity of the headache and rotatory dizziness had decreased, blood pressure was recorded at 128/78 mmHg, and consciousness remained stable. The documented outcomes in this report are limited to the third day.

The trajectory of the patient's clinical course—from the onset of symptoms, initial evaluation, and imaging studies, to the modification of management post-ICH diagnosis and

the clinical status on the third day—is summarized in Table 1 to illustrate the temporal relationship among symptoms, diagnostic findings, interventions, and initial clinical outcomes.

Table 1. Clinical timeline of the case

Time	Clinical and Diagnostic Findings	Management/Outcomes
Pre-ED	Severe rotatory dizziness accompanied by recurrent vomiting; had received symptomatic therapy at another facility.	Initial therapy prior to evaluation at the reporting hospital.
Day 0 – ED	GCS 15; blood pressure 114/67 mmHg; no hemiparesis observed; stable hemodynamic status.	Initial clinical evaluation.
Day 0 – Investigations	Initial laboratory tests; chest radiograph suggestive of bronchopneumonia.	Initial diagnosis of peripheral vertigo and bronchopneumonia.
Day 0 – Head CT	Right caudate nucleus hemorrhage with intraventricular extension and ventriculomegaly.	ICH diagnosis established, and management adjusted.
Days 0–3	Continuous clinical and neurological monitoring.	Mannitol administered; pharmacotherapy regimen re-evaluated.
Day 3	Headache and rotatory dizziness decreased; blood pressure 128/78 mmHg; consciousness stable.	Initial clinical improvement; long-term outcomes not yet documented.

Source: Patient's medical record

The patient provided verbal informed consent for the publication of the clinical information presented in this case report. The patient's anonymity was maintained by omitting direct personal identifiers from the manuscript. The clinical images included in this report were de-identified to remove unnecessary identifying information.

Discussions

A. Clinical Characteristics of Caudate Nucleus Hemorrhage and Its Mimicry of Peripheral Vertigo

This case illustrates an atypical presentation of caudate nucleus hemorrhage, in which severe vestibular symptoms predominated despite the absence of obvious focal neurological deficits. The caudate nucleus is a deep subcortical structure located close to the ventricular system, making hemorrhage in this region susceptible to intraventricular extension [5]. Previous reports of isolated caudate nucleus hemorrhage have identified headache and vomiting as common clinical manifestations [6]. Non-pharmacological approaches to headache management have also been explored in adolescent and college student populations [8]. In contrast, the initial presentation in this patient was dominated by severe rotatory vertigo and recurrent vomiting, initially suggesting a peripheral vestibular disorder. A comparable diagnostic challenge was reported by Zeyen et al., who described cerebellar hemorrhage initially misdiagnosed as unilateral vestibulopathy [9]. Although the hemorrhage location differed, this case report illustrates how intracranial hemorrhagic lesions may present with vestibular symptoms resembling peripheral disorders.

In the present case, the hemorrhage extended into the right lateral and third ventricles, accompanied by ventriculomegaly. Intraventricular hemorrhage may disrupt cerebrospinal fluid (CSF) circulation and contribute to hydrocephalus, a recognized complication of ICH [1]. These imaging findings provide a plausible basis for considering a central intracranial process underlying the patient's vomiting and vestibular symptoms. However, the specific mechanism responsible for the rotatory sensation cannot be established from the available clinical and imaging data. Therefore, this case does not establish caudate nucleus hemorrhage as a typical cause of peripheral vertigo; rather, it highlights that vestibular symptoms may accompany central intracranial lesions and should not be used in isolation to exclude an underlying neurological etiology.

B. Diagnostic Evaluation of Acute Vestibular Symptoms and Secondary ICH Etiologies in Young Adults

Acute dizziness or vertigo should be evaluated using a syndrome-based approach that considers symptom timing and patterns, neurological findings, and oculomotor examination. In patients with acute vestibular syndrome (AVS) accompanied by nystagmus, the Head-Impulse, Nystagmus, Test of Skew (HINTS) examination can help differentiate central from peripheral etiologies when performed by a trained clinician [7]. Routine brain computed tomography (CT) is not recommended as a screening test for all patients with AVS. In the present case, however, CT was performed because the symptoms were persistent and severe and the clinical course was inconsistent with a straightforward peripheral vestibular disorder, raising concern for an intracranial cause [7].

Documentation of nystagmus, HINTS findings, head impulse, test of skew, and gait assessment was unavailable. Consequently, the initial diagnosis of peripheral vertigo could not be fully evaluated retrospectively. This limitation highlights the importance of structured vestibular and neurological examinations in conjunction with appropriate neuroimaging.

Once ICH is identified, evaluation of its underlying etiology is particularly important in young adults without a history of hypertension, as the potential causes are diverse and include vascular, structural, hematological, and substance use-related factors [2,4]. The etiological spectrum also includes cerebral small vessel disease, emphasizing the need to consider age, hemorrhage location, risk factors, and neuroimaging findings collectively [10]. A cohort study involving 134 adults aged 18–44 years with nontraumatic ICH used the modified SMASH-UP classification to characterize primary and secondary hemorrhage mechanisms and identified differences in etiological patterns between pregnancy-associated and nonpregnancy-associated ICH [11]. These population-level findings illustrate etiological heterogeneity but cannot establish the cause of hemorrhage in an individual patient.

Current guidelines recommend vascular imaging as part of the etiological evaluation of young patients with deep ICH [1]. Computed tomography angiography (CTA) is useful for investigating macrovascular causes, while venous imaging should be considered when cerebral venous thrombosis is suspected. Digital subtraction angiography (DSA) serves as a reference standard for detecting macrovascular abnormalities, particularly in patients younger than 45 years with deep ICH when initial noninvasive imaging is inconclusive. Magnetic resonance angiography (MRA) may also complement the evaluation according to clinical findings and initial imaging results [1]. Similarly, the European Stroke Organisation (ESO) and European Association of Neurosurgical Societies (EANS) recommend a stepwise approach using CTA or MRA, with DSA considered in selected patients [12].

In the present patient, the age of 28 years, absence of a history of hypertension, deep caudate hemorrhage, and intraventricular extension supported consideration of a secondary etiology. Potential causes, including arteriovenous malformations (AVMs), intracranial aneurysms, dural arteriovenous fistulas, cavernous malformations, and cerebral venous thrombosis, therefore remain relevant differential diagnoses [1,4]. However, because CTA, MRA, DSA, and other advanced diagnostic investigations were unavailable, the underlying etiology could not be established. These conditions should therefore be regarded as diagnostic possibilities rather than confirmed causes.

C. Medication Safety and Acute Management Considerations in ICH

Medication reconciliation is an important clinical pharmacology component following the establishment of an intracerebral hemorrhage (ICH) diagnosis. Before the definitive diagnosis, the patient received various empirical and symptomatic therapies. Because the clinical rationale for these prescriptions was not fully documented, their administration cannot be retrospectively classified as prescribing errors. Following the diagnosis, each medication should be reassessed based on its indication, expected benefits, adverse effects, potential drug-disease interactions, bleeding and hemodynamic risks, and possible effects on neurological monitoring.

Pseudoephedrine, a sympathomimetic decongestant, may modestly increase systolic blood pressure and heart rate, with effects varying according to dose and formulation [13]. Although its hemodynamic effects at therapeutic doses are generally limited, potential cardiovascular and cerebrovascular effects warrant consideration in susceptible patients [14]. The European Medicines Agency (EMA) identified very rare but serious risks of posterior reversible encephalopathy syndrome (PRES) and reversible cerebral vasoconstriction syndrome (RCVS) associated with pseudoephedrine-containing medications [15]. In Indonesia, the Food and Drug Authority (BPOM) registers sustained-release combinations of pseudoephedrine hydrochloride and loratadine; this information verifies product composition and regulatory

status rather than establishing clinical effects [16]. In the present case, the indication for pseudoephedrine could not be determined from the available documentation. There was also no evidence that it caused the hemorrhage or hematoma expansion, and serial CT imaging was unavailable to assess changes in hematoma volume. Therefore, its necessity and benefits should be reassessed following the ICH diagnosis, with discontinuation considered if the indication is no longer relevant.

Ketorolac is a nonsteroidal anti-inflammatory drug (NSAID) that inhibits platelet function. Its prescribing information in the United States lists suspected or confirmed cerebrovascular bleeding as a contraindication [17]. Because ketorolac was administered before the ICH diagnosis, its risk profile and the suitability of alternative analgesic agents should be reassessed following confirmation of the hemorrhage, considering the patient's neurological condition.

Codeine has central antitussive and analgesic properties and may cause sedation and respiratory depression. In this case, codeine 20 mg three times daily was administered empirically as an antitussive in the context of the initial working diagnosis of bronchopneumonia, although the initial history documented that the patient denied cough. Indonesian product information identifies codeine as an antitussive, lists head injury and elevated intracranial pressure among its contraindications, and recognizes respiratory depression as a potential adverse effect [18]. The United States (US) prescribing information further warns that respiratory depression may cause carbon dioxide retention and increase intracranial pressure in susceptible patients [19]. Accordingly, the need for continued antitussive therapy following the ICH diagnosis should be reassessed, particularly regarding respiratory effects, sedation, and neurological monitoring.

Dimenhydrinate may cause drowsiness, which is relevant in patients requiring serial neurological examinations [20]. Its continued use therefore warrants reassessment once a central intracranial cause has been identified. Betahistine and flunarizine were administered when the symptoms were initially considered suggestive of peripheral vestibular disease. Their individual benefits following the ICH diagnosis cannot be established from the available case data; thus, their indications and the need for continued treatment should be evaluated separately, without assuming that they share the same risk profile as dimenhydrinate.

Contemporary neurocritical care recommendations emphasize individualized analgesia and sedation while preserving the ability to assess neurological function. The 2024 expert consensus recommends neurological examinations during analgesic and sedative therapy and emphasizes careful consideration of opioid-related adverse effects, including respiratory depression and alterations in consciousness [21]. A recent review similarly highlights that sedative and analgesic agents may affect neurological examination findings, supporting

individualized pharmacotherapy selection and careful monitoring in patients with acute brain injury [22].

Overall, this case emphasizes that medication reconciliation does not conclude merely with identifying the administered drugs, but must proceed with a re-evaluation once a definitive diagnosis alters the patient's clinical context. Medications prescribed in the acute phase for symptom management should be reviewed based on indications, benefits, adverse effect profiles, drug-disease interactions, and their potential impact on neurological monitoring. This approach allows for the objective rationalization of therapy tailored to the patient's specific clinical condition.

Table 2 summarizes selected medications and their principal risk considerations and reassessment needs following the ICH diagnosis. It is not intended as a comprehensive audit of all administered therapies or an assessment of the initial prescribing decisions.

Table 2. Medication reconciliation and pharmacotherapy risk profile during admission

Medication	Role in the case	Risk profile of concern	Evidence base	Implications for medication reconciliation
Pseudoe-phedrine	Sympathomimetic decongestant administered during the initial phase.	May elevate blood pressure and heart rate. Very rare risks of PRES and RCVS. No evidence that pseudoephedrine caused hemorrhage or hematoma expansion in this case.	Meta-analyses; pharmacolo-gical reviews; international regulatory information; Indonesian Food and Drug Authority (BPOM) product verification.	Following the ICH diagnosis, the necessity and benefits of pseudoephedrine should be reassessed. Discontinuation may be considered if the indication is no longer relevant.
Ketorolac	NSAID administered during the initial phase.	Inhibits platelet function. US prescribing information lists suspected or confirmed cerebrovascular bleeding as a contraindication.	Official US prescribing information.	Once ICH is identified, ketorolac's risk profile and the suitability of alternative analgesic agents should be reassessed according to the patient's neurological condition.
Codeine	Opioid antitussive administered empirically during the initial management of suspected broncho-pneumonia.	May cause sedation and respiratory depression. In susceptible patients, respiratory drive depression and carbon dioxide	Indonesian BPOM product information; official US prescribing information.	Following the ICH diagnosis, the need for continued antitussive therapy should be reassessed, considering its indication, respiratory effects,

Medication	Role in the case	Risk profile of concern	Evidence base	Implications for medication reconciliation
		retention may increase intracranial pressure (ICP).		and potential impact on neurological monitoring.
Dimenhy-drinate	Symptomatic medication for vestibular and nausea complaints.	May cause drowsiness, including at high doses.	Indonesian BPOM product information.	Its necessity should be reassessed once a central etiology is identified, particularly because of the need for serial neurological monitoring.
Betahistine and flunarizine	Symptomatic therapies administered when the complaints were considered suggestive of a peripheral vestibular disorder.	Individual benefits following ICH diagnosis cannot be assessed from the available case data; their risk profiles should not be equated with that of dimenhydrinate.	Case data; case-specific evidence unavailable.	Reassess the indications, expected benefits, and necessity of continuing therapy following the definitive diagnosis.
20% Mannitol	Hyperosmolar therapy administered after identification of caudate nucleus hemorrhage with intraventricular extension and ventriculomegaly.	An osmotic diuretic that can temporarily reduce cerebral edema and ICP. Monitoring of volume status, renal function, and fluid and electrolyte balance is required.	AHA/ASA guidelines and neurocritical care evidence support hyperosmolar therapy for temporary ICP reduction; benefits regarding long-term neurological outcomes remain uncertain [1,23].	Use should be tailored to the clinical condition and indications for ICP management. Clinical improvement was observed during admission, but the response cannot be attributed solely to mannitol. The regimen used in this case is not intended as a universal recommendation.

Sources: Patient's medical records, with modifications from various references.
Note: This table intentionally omits several medications administered to the patient. Ceftriaxone, azithromycin, ondansetron, sucralfate, inhalation therapies, and other treatments remain documented in the Case Presentation but are not included because they are less directly relevant to the neurological medication-safety discussion.

Beyond medication reconciliation, acute ICH management requires attention to blood pressure, ventricular enlargement, and ICP. The American Heart Association/American Stroke Association (AHA/ASA) recommends smooth and sustained systolic blood pressure (SBP) reduction in patients with mild-to-moderate ICH presenting with SBP of 150–220 mmHg, targeting approximately 140 mmHg and maintaining the level within 130–150 mmHg; reduction to below 130 mmHg should be avoided [1]. The 2026 European Stroke Organisation (ESO) update notes that the net benefit of intensive blood pressure lowering remains uncertain, although expert consensus supports an initial SBP target below 140 mmHg in selected patients

with small-to-moderate hematomas [24]. These recommendations should be individualized according to baseline blood pressure, hematoma characteristics, and clinical condition. In the present case, the initial blood pressure was 114/67 mmHg, outside the elevated-SBP range addressed by these recommendations; therefore, there was no indication for acute blood pressure reduction based on the available baseline data. Maintaining hemodynamic stability and avoiding unnecessary blood pressure fluctuations were more relevant considerations [1,24].

Ventriculomegaly should be interpreted in conjunction with the patient's neurological status. Intraventricular hemorrhage (IVH) with hydrocephalus may require ventricular drainage when it contributes to decreased consciousness [1]. In this case, the patient remained fully conscious, with a Glasgow Coma Scale (GCS) score of 15, and no direct ICP measurement was documented. Thus, the available findings do not establish that ventricular drainage was necessary at the time of diagnosis. Nevertheless, ventriculomegaly warranted close neurological monitoring and readiness for neurosurgical evaluation if clinical deterioration or signs of symptomatic hydrocephalus emerged.

Hyperosmolar therapy may be considered for the temporary reduction of ICP in patients with ICH, whereas prophylactic administration has not demonstrated a benefit in clinical outcomes [1]. Mannitol increases plasma osmolarity, promoting water movement from brain tissue into the intravascular compartment and thereby temporarily reducing cerebral edema and ICP. Neurocritical care evidence supports its use for ICP and cerebral edema reduction, although benefits regarding long-term neurological outcomes remain uncertain [24]. In this patient, mannitol was administered following identification of the caudate nucleus hemorrhage with intraventricular extension and ventriculomegaly, providing a pharmacological rationale for hyperosmolar therapy in the context of suspected elevated ICP. However, because direct ICP measurements were unavailable, the physiological response could not be quantified. The improvement in headache and rotatory dizziness by day 3 was an observed clinical outcome but could not be attributed solely to mannitol, given the concurrent pharmacotherapy adjustments and supportive care. Its use also requires monitoring of volume status, renal function, and fluid and electrolyte balance because osmotic diuresis may cause dehydration, electrolyte disturbances, and renal impairment [24]. Accordingly, the potential benefit of temporary ICP reduction should be weighed against the patient's physiological condition and the treatment's safety profile.

D. Lessons from the Diagnostic Challenge

An interdisciplinary consensus on acute isolated vertigo in the emergency department recommends structured history-taking, focused vestibular and neurological examinations, and recognition of clinical warning signs to guide further investigations and neuroimaging [25]. In

the present case, this framework highlights the importance of diagnostic reassessment when severe vestibular symptoms persist and are accompanied by recurrent vomiting, rather than relying solely on the initial impression of a peripheral vestibular disorder.

Conclusion

Caudate nucleus hemorrhage in a young adult without a history of hypertension may present atypically and mimic peripheral vertigo, even in the absence of obvious focal neurological deficits. Persistent or severe vestibular symptoms, particularly when accompanied by recurrent vomiting, warrant early consideration of central intracranial causes and appropriate neurological evaluation. In young adults with ICH, assessment of secondary etiologies should be considered according to clinical and neuroimaging findings. Following diagnosis, medication reconciliation and individualized reassessment of drug indications, expected benefits, bleeding and sedative risks, and drug-disease interactions are essential to medication safety during acute neurological care. However, as follow-up in this case was limited to the third day of hospitalization, long-term neurological and functional outcomes could not be determined.

Conflict of Interest

The authors declare no conflict of interest.

References

[1] S. M. Greenberg et al., "2022 guideline for the management of patients with spontaneous intracerebral hemorrhage: a guideline from the American Heart Association/American Stroke Association," in *Stroke*, vol. 53, no. 7, pp. e282–e361, 2022, doi: 10.1161/STR.0000000000000407

[2] H. Wang, J. Lin, L. Wang, X. Zhang, T. Zhou, C. Zhang, S. Zhang, and R. Hu, "Global, regional, and national burden of intracerebral hemorrhage in young adults from 1990 to 2021: a population-based study," in *Journal of the American Heart Association*, vol. 13, no. 21, Art. no. e037286, 2024, doi: 10.1161/JAHA.124.037286

[3] L. Firmanda et al., "Impact of cupping therapy on blood pressure in hypertension patients at Griya Bekam Az-Zahra," in *Journal of Health Sciences and Medical Development*, vol. 4, no. 1, pp. 10-19, 2025, doi: 10.56741/hesmed.v4i01.755

[4] M. Urfy and M. T. Mir, "When stroke strikes early: unusual causes of intracerebral hemorrhage in young adults," in *Journal of Clinical Medicine*, vol. 14, no. 23, Art. no. 8475, 2025, doi: 10.3390/jcm14238475

[5] M. E. Driscoll, P. C. Bollu, and P. Tadi, "Neuroanatomy, nucleus caudate," in *StatPearls [Internet]*, Treasure Island, FL, USA: StatPearls Publishing, 2026

[6] S. Çomoğlu and Ş. Özbakır, "Isolated caudate nucleus hemorrhage during the acute period of stroke," in *Turkish Journal of Medical Sciences*, vol. 31, no. 4, pp. 355–357, 2001

[7] J. A. Edlow, C. Carpenter, M. Akhter, D. Khoujah, E. Marcolini, W. J. Meurer, D. Morrill, J. G. Naples, R. Ohle, R. Omron, S. Sharif, M. Siket, S. Upadhye, L. O. J. E. Silva, E. Sundberg, K. Tartt, S. Vanni, D. E. Newman-Toker, and F. Bellolio, "Guidelines for reasonable and appropriate care in the emergency department 3 (GRACE-3): acute dizziness and vertigo in the emergency department," in *Academic Emergency Medicine*, vol. 30, no. 5, pp. 442–486, 2023, doi: 10.1111/acem.14728

[8] Sukarmin and S. S. Mardiana, "The effect of neck exercises on headaches of adolescent: a case study of college students in Kudus, Indonesia," in *Journal of Health Sciences and Medical Development*, vol. 2, no. 3, pp. 147-158, 2023, doi: 10.56741/hesmed.v2i03.426

[9] T. Zeyen, T. Klockgether, C. Schaub, D. Paech, T. Vogt, and D. Kurzwelly, "Cerebellar hemorrhage masquerading as unilateral vestibulopathy: A case report," in Case Reports in Neurological Medicine, vol. 2025, Art. no. 9611619, 2025, doi: 10.1155/crnm/9611619.

[10] C. Periole, C. Blanc, L. Calvière, L. Fontaine, A. Viguier, J. F. Albucher, F. Chollet, F. Bonneville, J. M. Olivot, and N. Raposo, "Prevalence and characterization of cerebral small vessel disease in young adults with intracerebral hemorrhage," in *International Journal of Stroke*, vol. 18, no. 1, pp. 102–108, 2023, doi: 10.1177/17474930221093526

[11] M. Sariyeva, N. Haghighi, A. Mitchell, W. A. Booker, N. H. Petersen, A. D. Shields, S. Ghoshal, S. Agarwal, S. Park, J. Claassen, E. S. Connolly, D. J. Roh, and E. C. Miller, "Primary and secondary intracerebral hemorrhage in pregnant and nonpregnant young adults by SMASH-UP criteria," in Journal of the American Heart Association, vol. 13, no. 7, Art. no. e034032, 2024, doi: 10.1161/JAHA.123.034032.

[12] T. Steiner et al., "European Stroke Organisation (ESO) and European Association of Neurosurgical Societies (EANS) guideline on stroke due to spontaneous intracerebral haemorrhage," in *European Stroke Journal*, vol. 10, no. 4, pp. 1007–1086, 2025, doi: 10.1177/23969873251340815

[13] S. M. Salerno, J. L. Jackson, and E. P. Berbano, "Effect of oral pseudoephedrine on blood pressure and heart rate: a meta-analysis," in *Archives of Internal Medicine*, vol. 165, no. 15, pp. 1686–1694, 2005, doi: 10.1001/archinte.165.15.1686

[14] K. Głowacka and A. Wiela-Hojeńska, "Pseudoephedrine—benefits and risks," in *International Journal of Molecular Sciences*, vol. 22, no. 10, Art. no. 5146, 2021, doi: 10.3390/ijms22105146

[15] European Medicines Agency, "EMA confirms measures to minimise the risk of serious side effects with medicines containing pseudoephedrine," 2024. [Online]. Available: https://www.ema.europa.eu/. [Accessed: Oct. 8, 2026]

[16] Badan Pengawas Obat dan Makanan Republik Indonesia (BPOM RI), "Daftar obat komparator uji ekivalensi yang terdaftar di Indonesia: Pseudoefedrin HCl/Loratadine kapsul lepas lambat 120 mg/5 mg," Jakarta, Indonesia. [Eng. Trans.: List of comparator drugs for equivalence testing registered in Indonesia: Pseudoephedrine HCl/Loratadine prolonged-release capsules 120 mg/5 mg]

[17] DailyMed, "Ketorolac tromethamine tablet: official drug label," Bethesda, MD, USA: National Library of Medicine, 2022

[18] Badan Pengawas Obat dan Makanan Republik Indonesia (BPOM RI), "Codeine phosphate hemihydrate: Informasi Produk," Jakarta, Indonesia, 2023. [Eng. Trans.: Codeine phosphate hemihydrate: Product information]

[19] DailyMed, "Codeine sulfate tablets: full prescribing information," Bethesda, MD, USA: National Library of Medicine, 2026

[20] Badan Pengawas Obat dan Makanan Republik Indonesia (BPOM RI), "Dramamine (dimenhydrinate) 50 mg tablet: Lembar Informasi Pasien/Informasi Produk," Jakarta, Indonesia, 2024. [Eng. Trans.: Dramamine (dimenhydrinate) 50 mg tablet: Patient information leaflet/product information]

[21] L. L. Zhang et al., "Chinese expert consensus on sedation and analgesia for neurocritical care patients," in Chinese Medical Journal, vol. 137, no. 11, pp. 1261–1263, 2024, doi: 10.1097/CM9.0000000000003084.

[22] Z. I. Merhavy, T. Raeburn, G. M. Torres-Ayala, M. A. McCulloch, and T. C. Varkey, "Sedation and analgesia strategies in the neuro intensive care unit," in World Journal of Critical Care Medicine, vol. 14, no. 4, Art. no. 111787, 2025, doi: 10.5492/wjccm.v14.i4.111787.

[23] A. M. Cook, G. M. Jones, G. W. J. Hawryluk, P. Mailloux, D. McLaughlin, A. Papangelou, S. Samuel, S. Tokumaru, C. Venkatasubramanian, C. Zacko, L. L. Zimmermann, K. Hirsch, and L. Shutter, "Guidelines for the acute treatment of cerebral edema in neurocritical care patients," in *Neurocritical Care*, vol. 32, no. 2, pp. 647–666, 2020, doi: 10.1007/s12028-020-00959-7

[24] E. C. Sandset et al., "2025 update to European Stroke Organisation (ESO) guideline on blood pressure management in acute ischaemic stroke and intracerebral haemorrhage," in *European Stroke Journal*, vol. 11, no. 5, Art. no. aakag004, 2026, doi: 10.1093/esj/aakag004

[25] S. Vanni et al., "Consensus paper on the management of acute isolated vertigo in the emergency department," in Internal and Emergency Medicine, vol. 19, no. 5, pp. 1181–1202, 2024, doi: 10.1007/s11739-024-03664-x.

Authors



Susilo, M.D., Sp.N. is a neurologist and lecturer at the Department of Neurology, Faculty of Medicine and Health Sciences, Universitas Kristen Krida Wacana, Jakarta, Indonesia, with a strong clinical focus on central and peripheral nervous system disorders. He earned his medical degree from Universitas Kristen Krida Wacana and completed his Neurology Specialist training at Universitas Hasanuddin. Active in clinical education and patient care, he is a member of the Indonesian Medical Association (IDI) and the Indonesian Neurological Association (PERDOSSI). (email: susilo@ukrida.ac.id).



Ferina Angelia, M.D., Sp.F.K. is a lecturer, consultant in clinical pharmacology, and researcher at the Department of Pharmacology, Faculty of Medicine and Health Sciences, Universitas Kristen Krida Wacana, Jakarta, Indonesia. She graduated cum laude from the Clinical Pharmacology Specialist Program at the Faculty of Medicine, Universitas Indonesia. She is a frequent speaker at medical and health-related symposia and has authored numerous scientific publications and books. (email: ferina.angelia@ukrida.ac.id).



Steven Sakasasmita, M.D., M.Sc., Sp.N. is a neurologist and lecturer at the Department of Neurology, Faculty of Medicine and Health Sciences, Universitas Kristen Krida Wacana, Jakarta, Indonesia. He completed his Neurology Specialist training and earned his Master of Health Science from Universitas Hasanuddin, focusing on complex neurological conditions such as stroke. He is a member of IDI and PERDOSSI. (email: steven.sakasasmita@ukrida.ac.id).